2023 MID-ATLANTIC CONFERENCE

11th ANNUAL CURRENT CONCEPTS IN

VASCULAR THERAPIES

2023

Hilton Virginia Beach Oceanfront
Virginia Beach, Virginia

APRIL 20-22

The future is here now. There is nearly no role for open thoracoabdominal aortic surgery

Jean M. Panneton, MD, FRCSC, FACS
Professor of Surgery,
Chief & Program Director
Division of Vascular Surgery
Eastern Virginia Medical School
Co-Director, Sentara Aortic Center
Norfolk, VA

EVMS Eastern Virginia Medical School | SENTARA®

pannetjm@evms.edu

Disclosures

Consultant: Endospan, Endologix, Getinge, Medtronic Inc, Terumo Aortic, Philips Volcano, WL Gore
Speakers' Bureau: Medtronic Inc., Penumbra, Terumo Aortic, WL Gore
Advisory Board: Medtronic Inc.

Open Thoracoabdominal aortic surgery

Why is there a need for endovascular aortic therapy

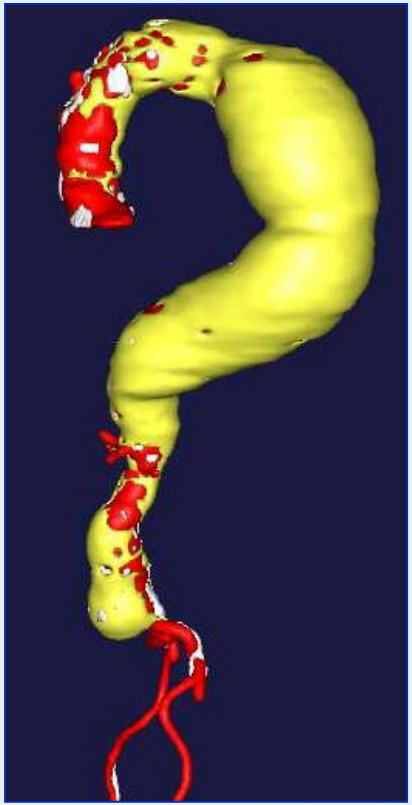

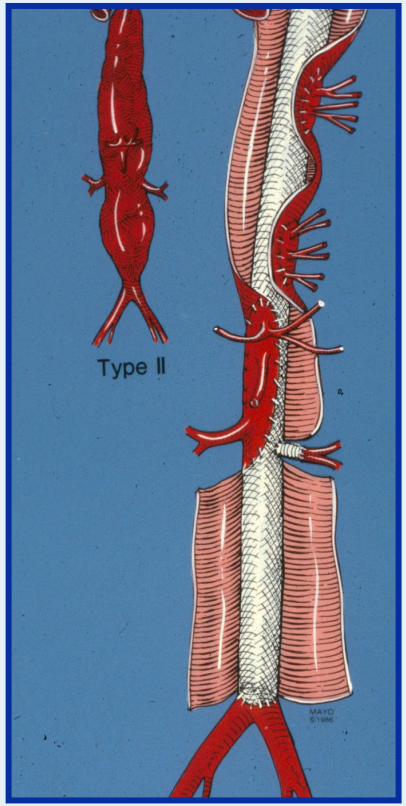

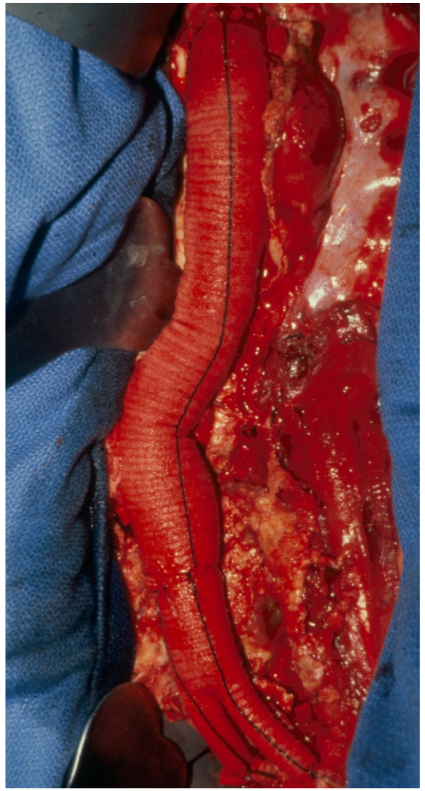

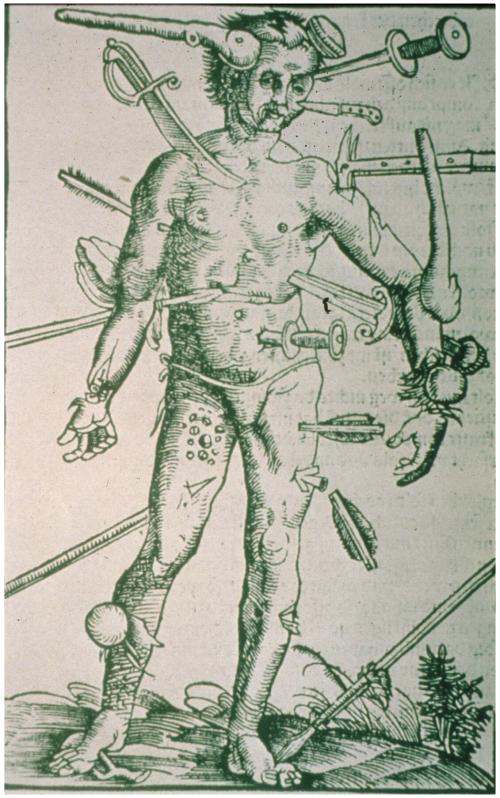

Mortality & Morbidity of 3500 TAAA

In hospital mortality	12%	(4-35%)
Respiratory failure	32%	(16-43%)
Renal dysfunction	18%	(4-37%)
Paraplegia / paresis	14%	(4-32%)
Need for dialysis	9%	(0-27%)
Myocardial infarction	11%	(2-23%)
Reoperation for bleeding	7%	(3-29%)
Coagulopathy	4%	(4-24%)
Sepsis	7%	(2-9%)
Stroke	3%	(3-7%)

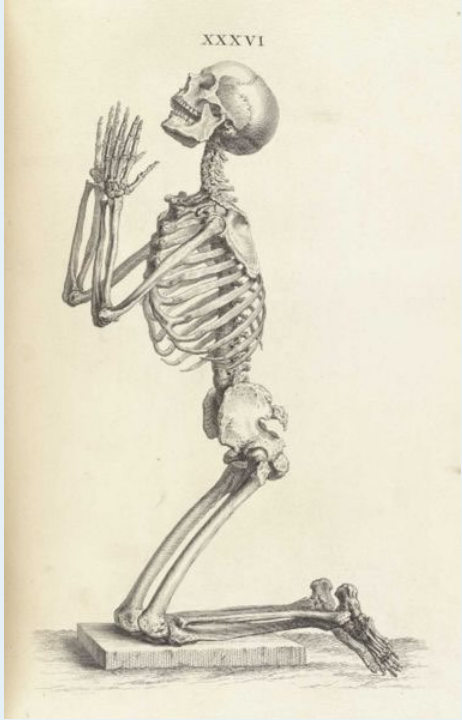

Panneton JM & Hollier LH, Ann Vasc Surg, 1995;503-514

Open Thoracoabdominal aortic surgery

TAAA Operative Mortality per hospital / surgeon volume

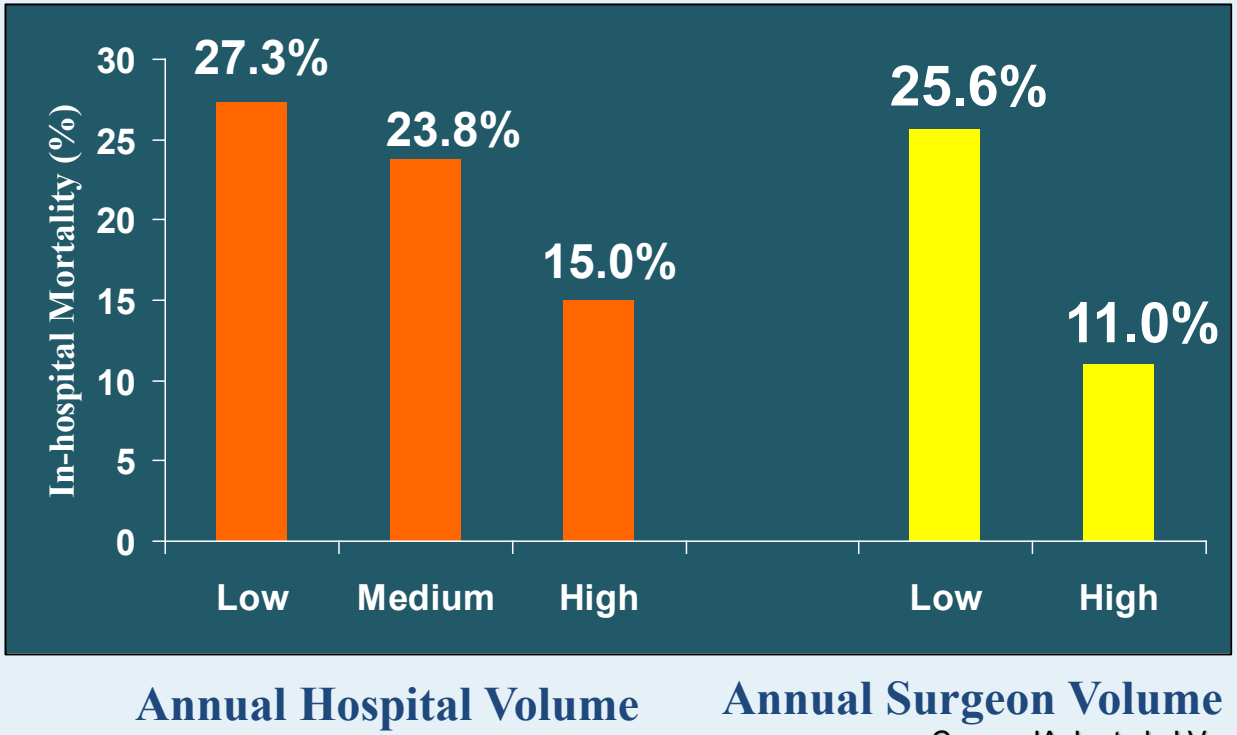

Cowan JA Jr et al, J Vasc Surg 2003;37:1169-74

Open Thoracoabdominal aortic surgery: Learning a different way

Open repair of complex aortic pathology is associated with significant operative mortality and morbidity and requires high case volume to acquire mastery and improve outcomes.

New technology and minimally invasive techniques are available to reconstruct the thoracoabdominal aorta and minimize risk and complications

TEVAR
PANNETJM@EVMS.EDU

Progress from the past to the present

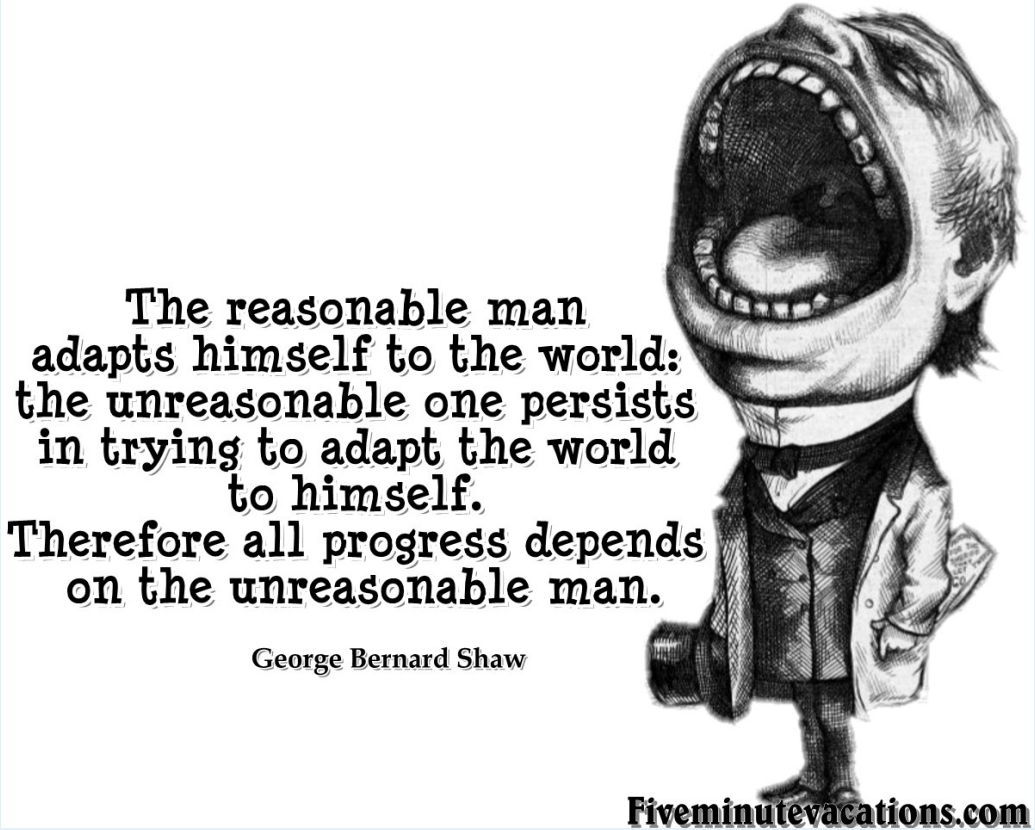

Adopting new technology



Jacques Plante in 1959

Grief-like Reaction:

Denial

Anger

Bargaining

Acceptance

TEVAR
PANNETJM@EVMS.EDU

The Future is here now

Devices for visceral vessels incorporation

Patient specific designs vs Off the shelf Devices

Cook Zenith Fenestrated Stent Graft



Vascutek Fenestrated Anaconda Endograft



Jotec Extra Design Multibranch Stent Graft

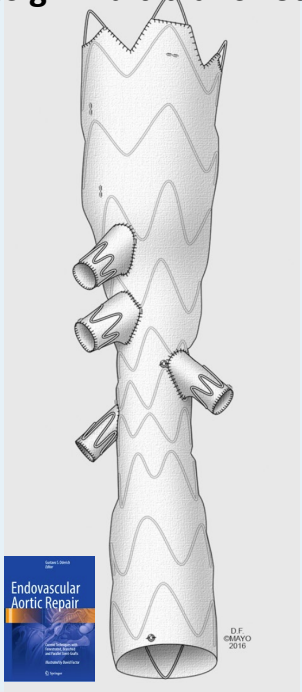

Off the shelf Devices

A. P-Branch, Cook

B. T-Branch, Cook

C. TAMBE, Gore

D. TAMBE, Gore

E. Ventana, Endologix

F. Colt, Jotec

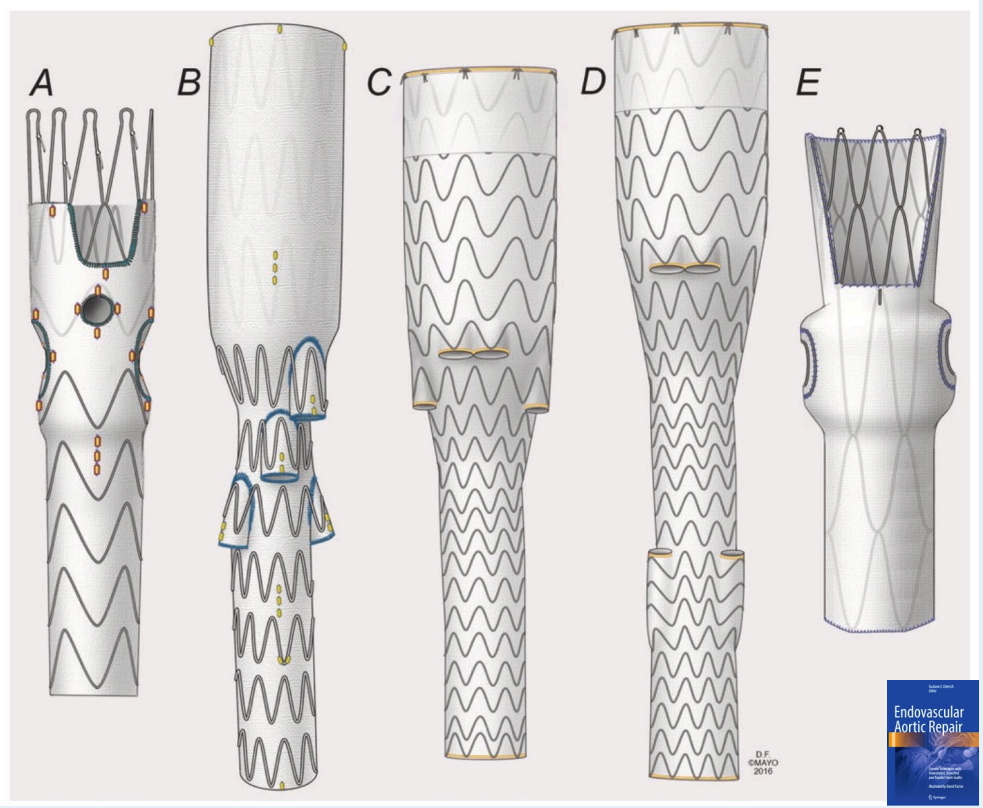

P-Branch

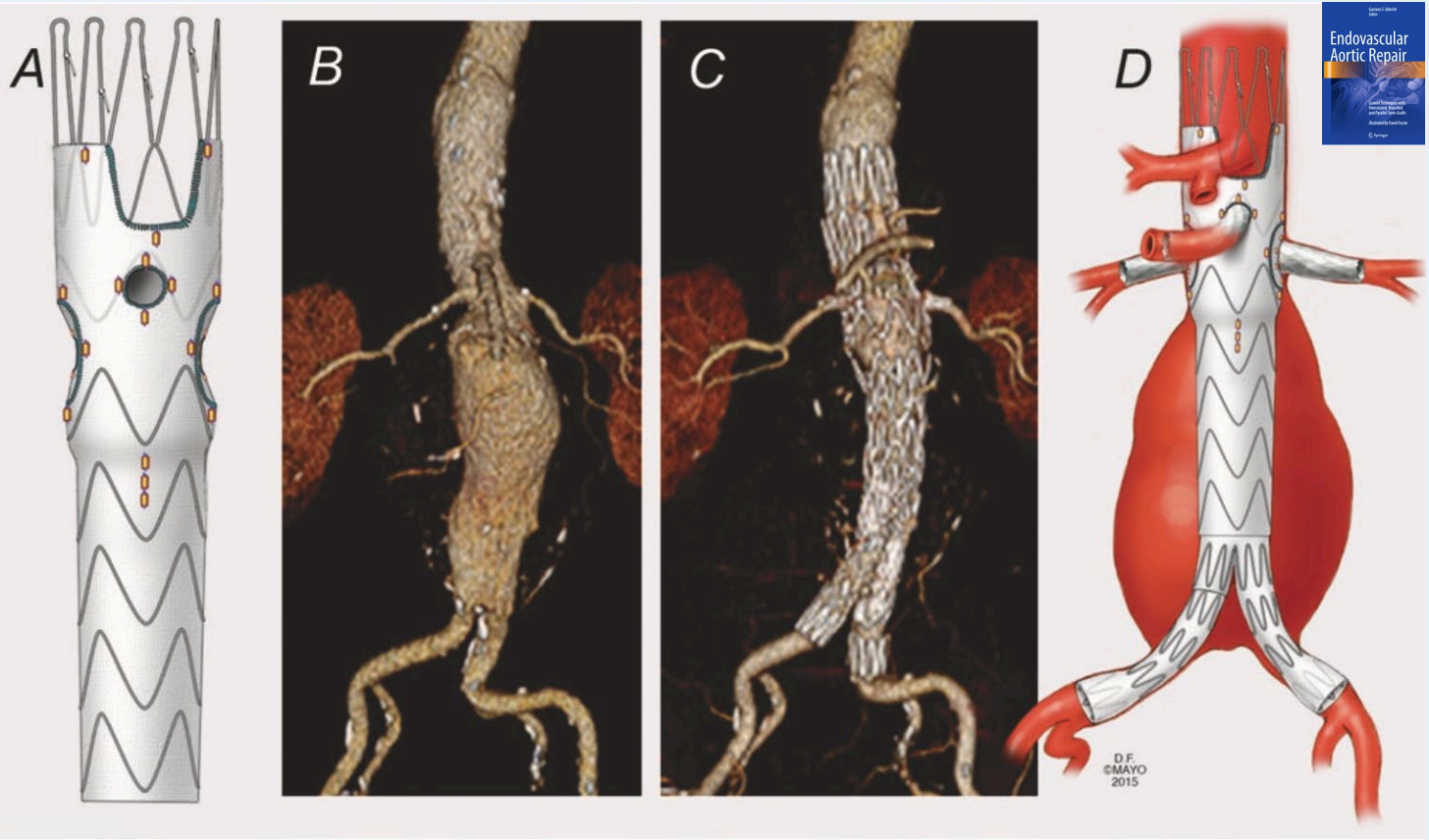

T-Branch

22 Fr system

4 branch device
All caudally oriented

No pre-wiring

Proximal diameter = 34 mm
Distal diameter = 18 mm
Length = 202 mm

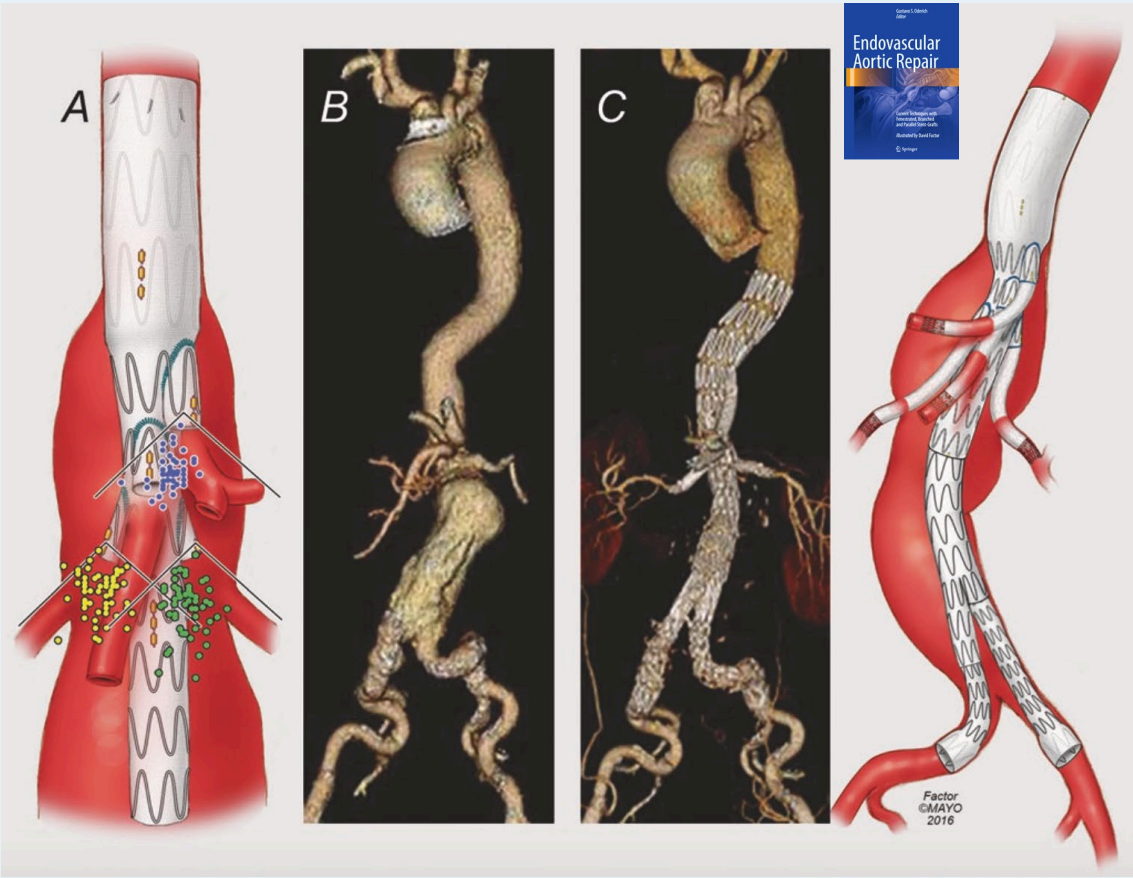

T-Branch: Outcomes

N = 542 patients
Mean age = 70.5 yrs
90% TAAAs

Table V. Technical success and morbidity

	Total patients (N = 542)	Early survival (n = 475)	Early mortality (n = 67)	*P* value
Technical success	526/542 (97)	464 (97.6)	62 (92)	.01
Technical failure	16	11	5	
Preoperative spinal drainage	72 (13)	62 (13)	10 (15)	[a]
Postoperative spinal drainage	22 (4)	11 (2)	11 (16)	[a]
No spinal drainage	448 (83)	402 (85)	46 (69)	[a]
Early any complication				.000
SIRS/sepsis	14 (2.6)	5 (1.1)	9 (13.4)	.000
MI	10 (1.8)	5 (1)	5 (7.5)	.000
Respiratory complication	12 (2.2)	6 (1.2)	6 (9)	.000
Stroke	14 (2.5)	5 (1)	9 (13.4)	.000
SCI	57 (10.5)			
Immediate temporary	28 (5.2)	20 (4.2)	8 (12)	.000
Immediate full	8 (1.5)	4 (0.8)	4 (6)	.000
Delayed temporary	7 (1.3)	7 (1.5)	0	
Delayed full	14 (2.6)	4 (0.8)	10 (15.2)	.000
No renal impairment	449 (83)	417 (88)	32 (48)	.000
Renal impairment	72 (13)	50 (10.5)	22 (33)	.000
Temporary dialysis	15 (3)	6 (1)	9 (13)	.000
Permanent dialysis	6 (1)	2 (0.5)	4 (6)	.000
Pancreatitis	13 (2.4)	7 (1.5)	6 (9)	.000
Mesenteric ischemia	7 (1.3)	1 (0.2)	6 (9)	.000
Ischemia colitis	9 (1.6)	2 (0.4)	7 (10.5)	.000
Wound infection	18 (3.3)	15 (3)	3 (4.5)	.63
Vascular access complication	42 (7.7)	24 (5.1)	18 (27)	.000

Early outcomes of the t-Branch off-the-shelf multi-branched stent graft in 542 patients for elective and urgent aortic pathologies — a retrospective observational study

Tilo Kölbel, MD,[a] Konstantinos Spanos, MD,[a,b] Katarzyna Jama, MD,[c] Christian-Alexander Behrendt, MD,[a] Giuseppe Panuccio, MD,[a] Ahmed Eleshra, MD,[a] Fiona Rohlffs, MD,[a] and Tomasz Jakimowicz, MD,[c] Hamburg, Germany; Larissa, Greece; and Warsaw, Poland

ABSTRACT

Objective: The t-Branch, a standardized off-the-shelf multi-branched stent graft has been used for the treatment of elective and urgent cases in aortic disease. The aim of this study was to assess the early outcomes in terms of technical success, mortality, and morbidity in >500 patients being treated with the t-Branch device.

Methods: A two-center retrospective observational study was undertaken including patients treated using the t-Branch (Cook Medical, Bloomington, IN) in elective or urgent settings for complex abdominal aortic aneurysm and thoraco-abdominal aortic aneurysm between 2014 and 2019 (early experience 2014-2016; late experience 2017-2019). Primary endpoints were technical success and early (30-day) mortality, and secondary endpoints were early morbidity, endoleak, and target vessel patency rates. Multivariable regression models were used to determine the independent association of risk factors with (1) mortality and (2) spinal cord ischemia.

Results: A total of 542 patients (mean age, 70.5 ± 8.5 years; 388 men [72%]; mean aneurysm diameter, 7.5 ± 2.5 cm) were included (63% elective; 90% thoraco-abdominal aortic aneurysm). The technical success rate was 97% (526/542) (elective, 96.7% [328/339] vs urgent, 97.6% [208/213]). The total 30-day mortality rate was 12.3% (8.5% in elective, 15% in symptomatic, and 30% in contained rupture). After multivariate regression analysis, the mortality rate was associated with older age (odds ratio [OR], 1.07; 95% confidence interval [CI], 1.03-1.11; $P < .001$) and with lower baseline glomerular filtration rate (OR, 0.98; 95% CI, 0.98-0.99; $P < .001$). In elective cases, the mortality rate was associated with a history of coronary artery disease (OR, 0.26; 95% CI, 0.09-0.73; $P < .011$) and higher body mass index (OR, 0.87; 95% CI, 0.77-0.98; $P < .027$). In urgent cases, the mortality rate was associated with older age, (OR, 1.07; 95% CI, 1.02-1.13; $P < .010$) and lower baseline glomerular filtration rate (OR, 0.97; 95% CI, 0.95-0.99; $P < .001$). The spinal cord ischemia rate was 10.5% (6.5% temporary, 4% permanent) and was associated with the early study period (OR, 2.01; 95% CI, 1.03-3.89; $P < .038$). The renal impairment rate was 13%; the stroke rate was 2.5%, and the myocardial infarction rate was 1.8%, whereas the access complications rate was 7.7%. On early computed tomography angiography, the primary patency rate for the right renal artery was 99.6%, for the left renal artery was 100%, for the superior mesenteric artery was 99.4%, and for the coeliac trunk artery was 99.8%. The endoleak I and III rates were 2.7% (15/542) and 2.7% (15/542), respectively.

Conclusions: Elective and urgent use of the t-Branch multi-branched off-the shelf stent graft showed high technical success and early target vessel patency rates. Early mortality and morbidity rates were acceptable. (J Vasc Surg 2021;■:1-8.)

Keywords: Thoraco-abdominal aortic aneurysm; T-branch; Endovascular repair; Spinal cord ischemia; Off-the-shelf stent graft

Kobel T et al, J Vasc Surg 2021

EVMS Eastern Virginia Medical School | SENTARA®

TAMBE

4 branch device

2 upper downward branches

2 lower upward branches

Compatible for proximal extension with cTAG or distal extension with Excluder

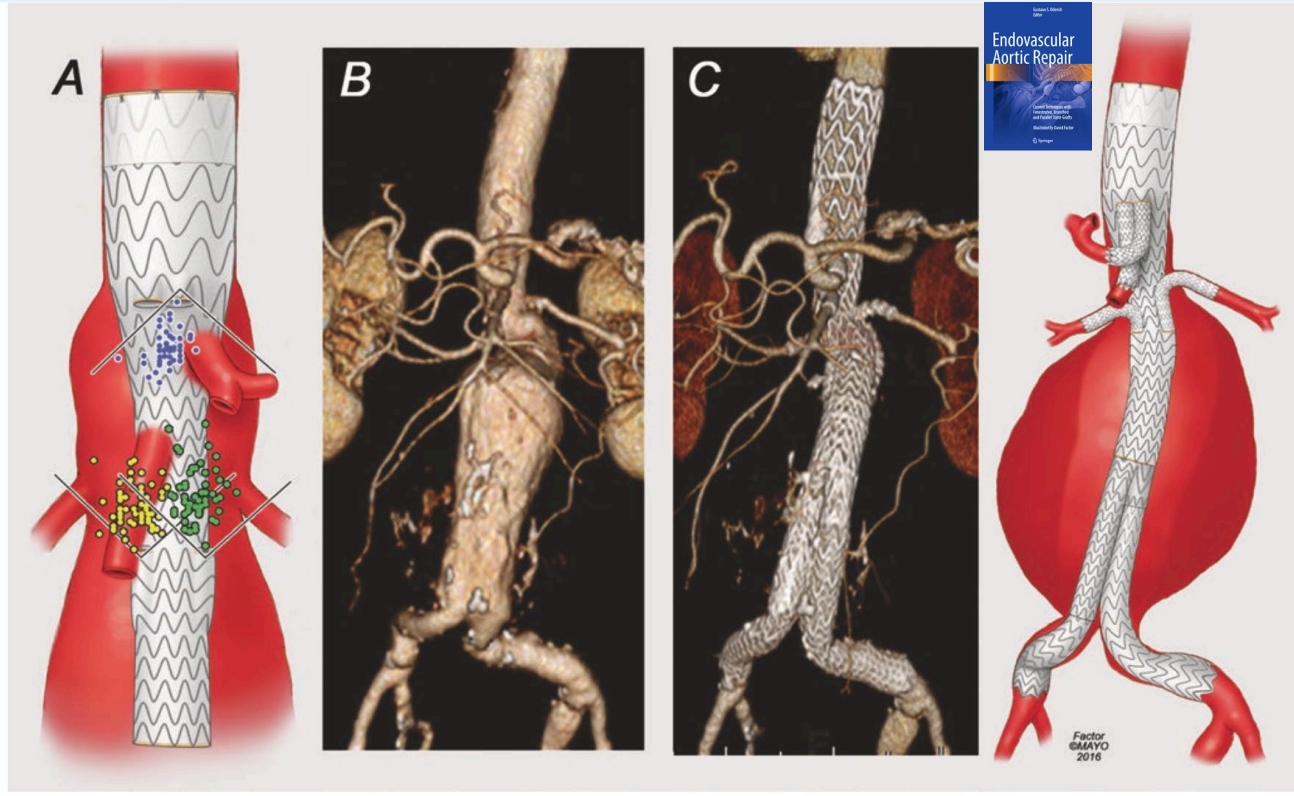

TAMBE

22 Fr sheath femoral art

12 Fr sheath axillary art

Proximal diameters: 31 & 37mm

Length = 160 mm

4 caudally oriented branches

Bridging stents: VBX

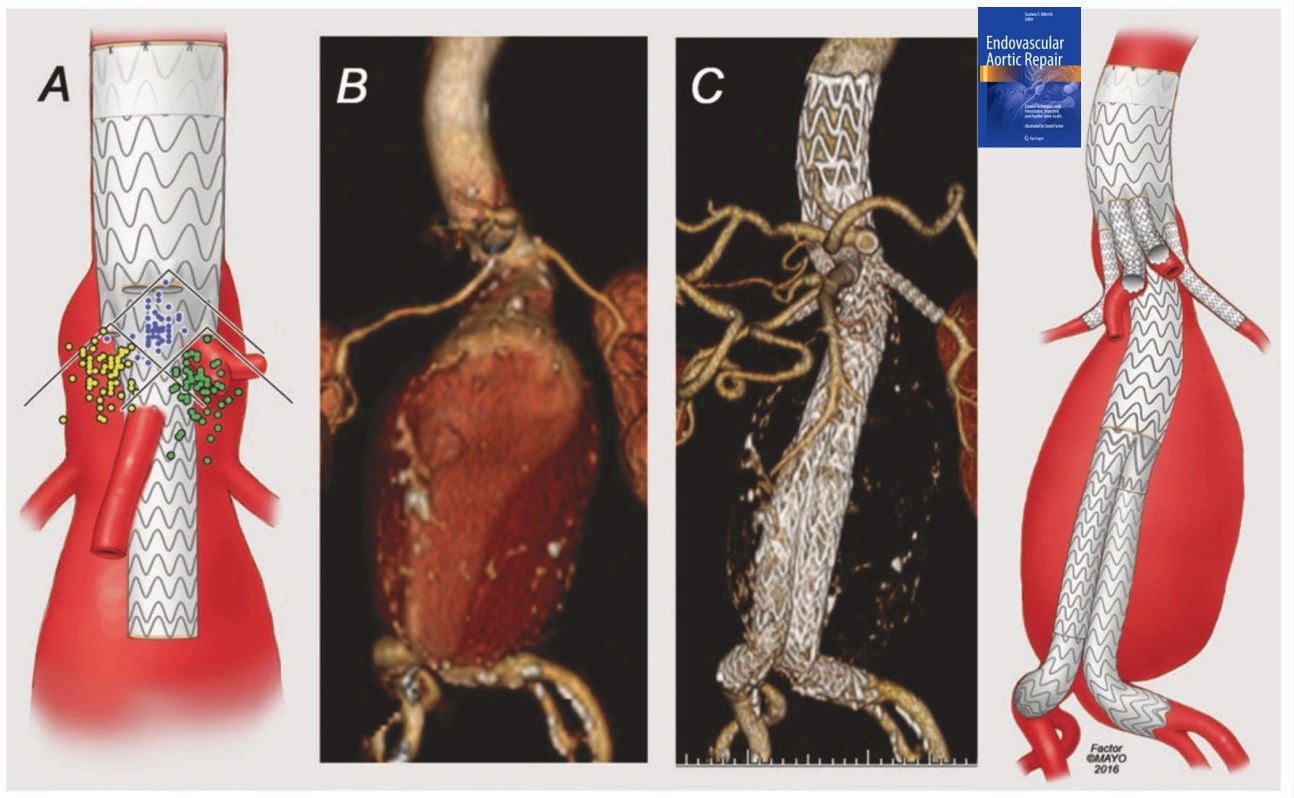

TAMBE

22 Fr sheath femoral art

12 Fr sheath axillary art

Proximal diameters: 31 & 37mm

Length = 160 mm

4 caudally oriented branches

Bridging stents: VBX

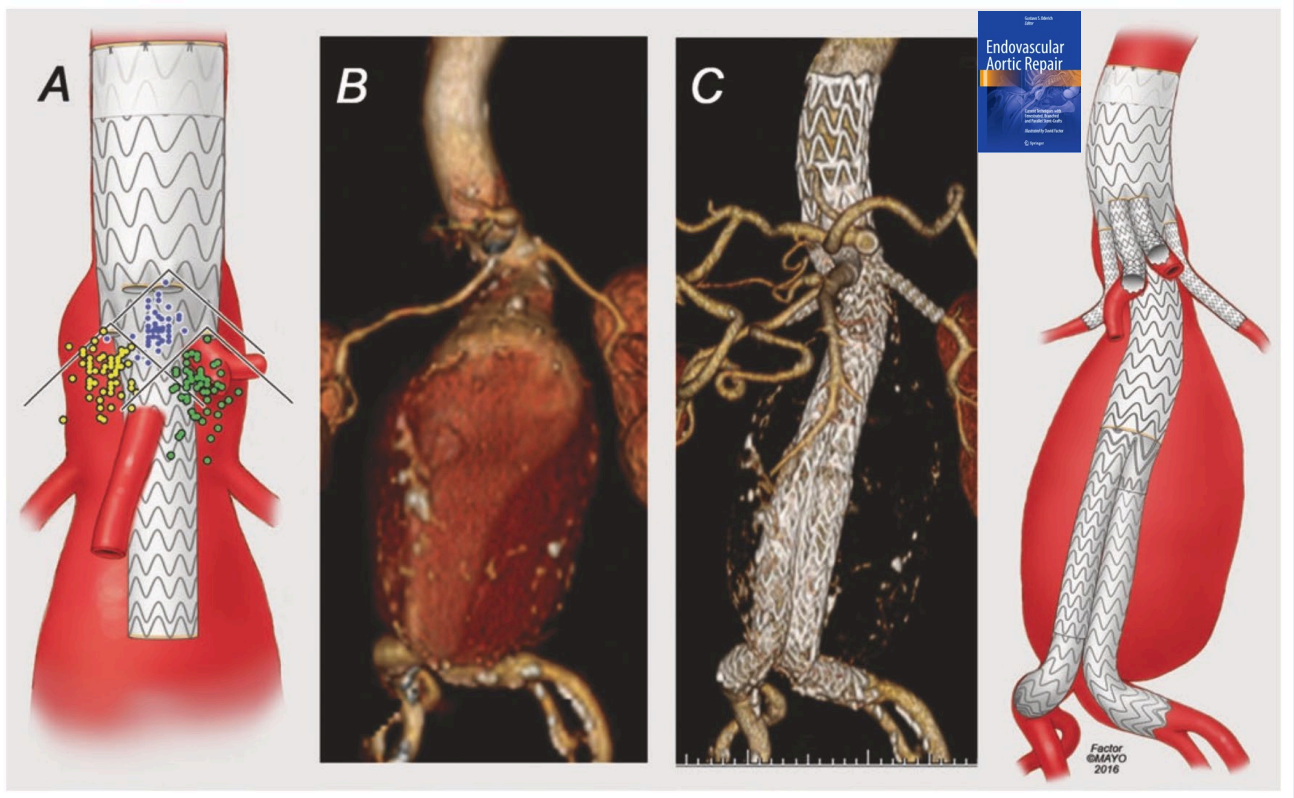

TAMBE: Anatomic Inclusion Criteria

Table II. Anatomic inclusion criteria for treatment of extended thoracoabdominal aneurysm (*E-TAA*) and limited thoracoabdominal aneurysm (*L-TAA*) according to the TAMBE investigational instructions for use (IFU)

Access feasibility
Diameter of iliac/femoral access ≥8.2 mm (22F DrySeal OD)
Diameter of one brachial/axillary access ≥4.7 mm (12F DrySeal OD)
Aortic feasibility
Length of the proximal (supraceliac) aortic neck ≥20 mm
Diameter of the proximal (supraceliac) aortic neck
22-34 mm (if TAMBE alone implant is planned for L-TAA)
19.5-32 mm (if proximal CTAG implant is required for E-TAA)
Aortic neck angle ≤60 degrees at the proximal seal zone or overall zone with thoracic CTAG
Inner aortic diameter (lumen) at the level of the visceral vessels' origin ≥20 mm
Visceral feasibility
No more than 4 visceral vessels providing significant splanchnic and renal perfusion
Diameter of renal arteries (ID) 4-10 mm
Diameter of celiac and superior mesenteric artery (ID) 5-12 mm
Length of each visceral vessel landing zone ≥15 mm
Celiac and superior mesenteric portal outlet 10-30 mm above the celiac trunk
Celiac trunk to aortic bifurcation distance ≥95 mm
Iliac artery diameter of 8-25 mm and seal zone length ≥10 mm

ID, Inner diameter; *OD*, outer diameter.

Cambiaghi T et al, J Vasc Surg 2021;73:22-30

TAMBE: Applicability

N = 227 patients
with TAAAs & Pararenal AAAs

L-TAA : N = 61
Type IV TAAAs & ParaAAAs

E-TAA : N = 166
Type I, II & III TAAAs

	L - TAA	E-TAA
Access feasibility	85%	79%
Aortic feasibility	74%	48%
Visceral vessel feasibility	72%	63%
Overall feasibility	49%	23%

The different feasibility rate was related to a difference in aortic feasibility between L-TAA and E-TAA (74% vs 48%; P = .0008) because of the lack of a dedicated tapered thoracic component.

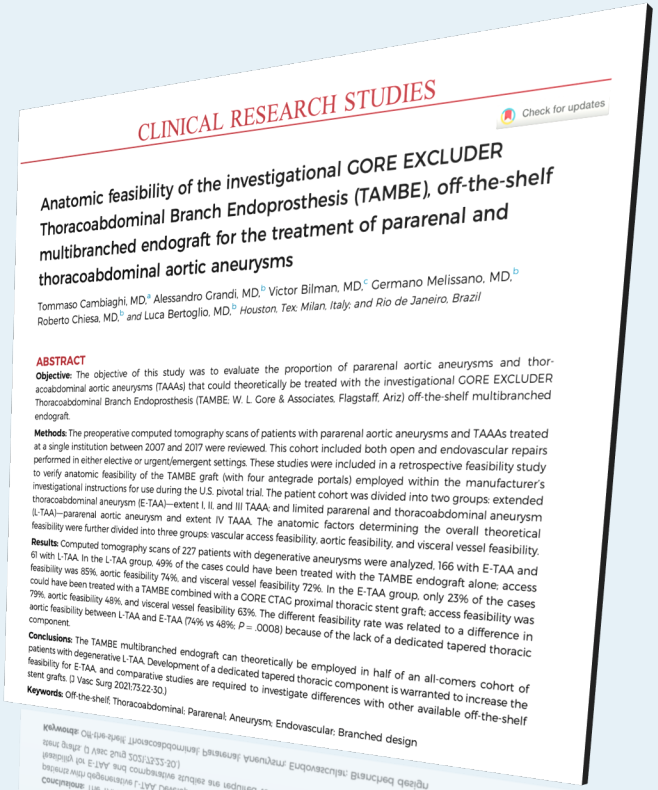

CLINICAL RESEARCH STUDIES

Check for updates

Anatomic feasibility of the investigational GORE EXCLUDER Thoracoabdominal Branch Endoprosthesis (TAMBE), off-the-shelf multibranched endograft for the treatment of pararenal and thoracoabdominal aortic aneurysms

Tommaso Cambiaghi, MD,[a] Alessandro Grandi, MD,[b] Victor Bilman, MD,[c] Germano Melissano, MD,[b] Roberto Chiesa, MD,[b] and Luca Bertoglio, MD,[b] Houston, Tex; Milan, Italy; and Rio de Janeiro, Brazil

ABSTRACT

Objective: The objective of this study was to evaluate the proportion of pararenal aortic aneurysms and thoracoabdominal aortic aneurysms (TAAAs) that could theoretically be treated with the investigational GORE EXCLUDER Thoracoabdominal Branch Endoprosthesis (TAMBE; W. L. Gore & Associates, Flagstaff, Ariz) off-the-shelf multibranched endograft.

Methods: The preoperative computed tomography scans of patients with pararenal aortic aneurysms and TAAAs treated at a single institution between 2007 and 2017 were reviewed. This cohort included both open and endovascular repairs performed in either elective or urgent/emergent settings. These studies were included in a retrospective feasibility study to verify anatomic feasibility of the TAMBE graft (with four antegrade portals) employed within the manufacturer's investigational instructions for use during the U.S. pivotal trial. The patient cohort was divided into two groups: extended thoracoabdominal aneurysm (E-TAA)—extent I, II, and III TAAA; and limited pararenal and thoracoabdominal aneurysm (L-TAA)—pararenal aortic aneurysm and extent IV TAAA. The anatomic factors determining the overall theoretical feasibility were further divided into three groups: vascular access feasibility, aortic feasibility, and visceral vessel feasibility.

Results: Computed tomography scans of 227 patients with degenerative aneurysms were analyzed, 166 with E-TAA and 61 with L-TAA. In the L-TAA group, 49% of the cases could have been treated with the TAMBE endograft alone: access feasibility was 85%, aortic feasibility 74%, and visceral vessel feasibility 72%. In the E-TAA group, only 23% of the cases could have been treated with a TAMBE combined with a GORE CTAC proximal thoracic stent graft; access feasibility was 79%, aortic feasibility 48%, and visceral vessel feasibility 63%. The different feasibility rate was related to a difference in aortic feasibility between L-TAA and E-TAA (74% vs 48%; $P = .0008$) because of the lack of a dedicated tapered thoracic component.

Conclusions: The TAMBE multibranched endograft can theoretically be employed in half an all-comers cohort of patients with degenerative L-TAA. Development of a dedicated tapered thoracic component is warranted to increase the feasibility for E-TAA, and comparative studies are required to investigate differences with other available off-the-shelf stent grafts. (J Vasc Surg 2021;73:22-30.)

Keywords: Off-the-shelf; Thoracoabdominal; Pararenal; Aneurysm; Endovascular; Branched design

Cambiaghi T et al, J Vasc Surg 2021;73:22-30

EVMS Eastern Virginia Medical School | SENTARA®

TAMBE: Outcomes

Early Feasibility Study
N = 13 patients
N = 52 vessels
Pararenal AAA or type IV TAAA

Technical success rate = 92%

Target vessel loss = 2%

Operative mortality = 0%

30-day MAEs = 31%

Early reintervention for type Ic endoleak = 2%

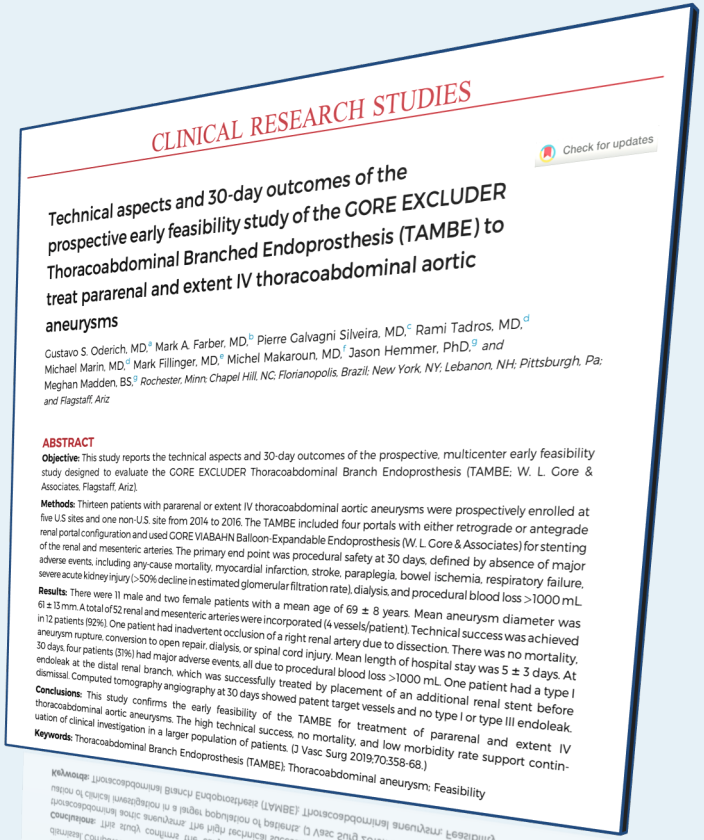

CLINICAL RESEARCH STUDIES

Check for updates

Technical aspects and 30-day outcomes of the prospective early feasibility study of the GORE EXCLUDER Thoracoabdominal Branched Endoprosthesis (TAMBE) to treat pararenal and extent IV thoracoabdominal aortic aneurysms

Gustavo S. Oderich, MD,[a] Mark A. Farber, MD,[b] Pierre Galvagni Silveira, MD,[c] Rami Tadros, MD,[d] Michael Marin, MD,[e] Mark Fillinger, MD,[f] Michel Makaroun, MD,[f] Jason Hemmer, PhD,[g] and Meghan Madden, BS,[g] *Rochester, Minn; Chapel Hill, NC; Florianopolis, Brazil; New York, NY; Lebanon, NH; Pittsburgh, Pa; and Flagstaff, Ariz*

ABSTRACT

Objective: This study reports the technical aspects and 30-day outcomes of the prospective, multicenter early feasibility study designed to evaluate the GORE EXCLUDER Thoracoabdominal Branch Endoprosthesis (TAMBE; W. L. Gore & Associates, Flagstaff, Ariz).

Methods: Thirteen patients with pararenal or extent IV thoracoabdominal aortic aneurysms were prospectively enrolled at five U.S sites and one non-U.S. site from 2014 to 2016. The TAMBE included four portals with either retrograde or antegrade renal portal configuration and used GORE VIABAHN Balloon-Expandable Endoprosthesis (W. L. Gore & Associates) for stenting of the renal and mesenteric arteries. The primary end point was procedural safety at 30 days, defined by absence of major adverse events, including any-cause mortality, myocardial infarction, stroke, paraplegia, bowel ischemia, respiratory failure, severe acute kidney injury (>50% decline in estimated glomerular filtration rate), dialysis, and procedural blood loss >1000 mL.

Results: There were 11 male and two female patients with a mean age of 69 ± 8 years. Mean aneurysm diameter was 61 ± 13 mm. A total of 52 renal and mesenteric arteries were incorporated (4 vessels/patient). Technical success was achieved in 12 patients (92%). One patient had inadvertent occlusion of a right renal artery due to dissection. There was no mortality, aneurysm rupture, conversion to open repair, dialysis, or spinal cord injury. Mean length of hospital stay was 5 ± 3 days. At 30 days, four patients (31%) had major adverse events, all due to procedural blood loss >1000 mL. One patient had a type I endoleak at the distal renal branch, which was successfully treated by placement of an additional renal stent before dismissal. Computed tomography angiography at 30 days showed patent target vessels and no type I or type III endoleak.

Conclusions: This study confirms the early feasibility of the TAMBE for treatment of pararenal and extent IV thoracoabdominal aortic aneurysms. The high technical success, no mortality, and low morbidity rate support continuation of clinical investigation in a larger population of patients. (J Vasc Surg 2019;70:358-68.)

Keywords: Thoracoabdominal Branch Endoprosthesis (TAMBE); Thoracoabdominal aneurysm; Feasibility

Oderich GS et al, J Vasc Surg 2019;70:358-68

EVMS Eastern Virginia Medical School | SENTARA®

COLT: Outcomes

From the Society for Vascular Surgery

Check for updates

Preliminary results from a multicenter Italian registry on the use of a new branched device for the treatment of thoracoabdominal aortic aneurysms

Domenico Angiletta, MD,[a] Gabriele Piffaretti, MD, PhD,[b] Isabella Patruno, MD,[a] Paola Wiesel, MD,[a] Sergio Zacà, MD,[a] Rainhold Perkmann, MD,[c] Michele Antonello, MD,[d] Ruth L. Bush, MD, JD, MPH,[e] *and* Raffaele Pulli, MD,[a] COLT Registry Group, *Bari, Varese, Bolzano, and Padua, Italy; and Houston, Tex*

N = 16 patients
Median age = 72.5 yrs

Technical success rate = 87.5%
Operative mortality = 19%
Mean follow-up = 8 months
No type I & III endoleaks
Primary patency = 98%

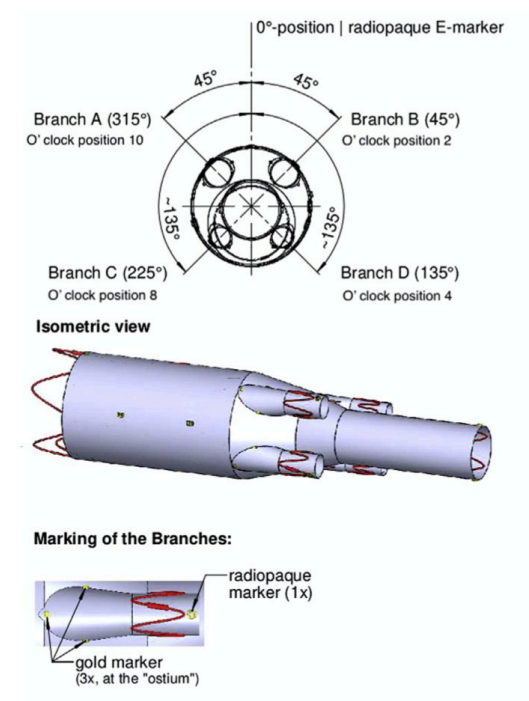

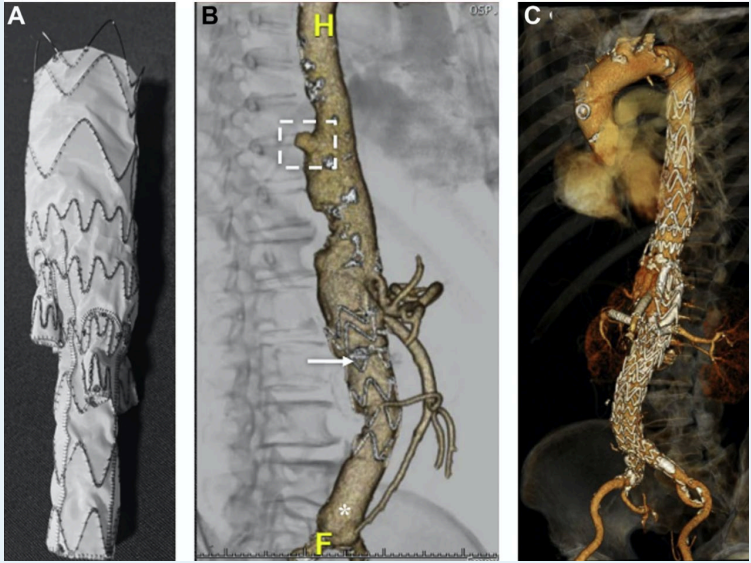

J Vasc Surg 2021;74:404-13.

Off the shelf Devices: Anatomic Feasibility Comparison

Comparison of anatomic feasibility of three different multibranched off-the-shelf stent-grafts designed for thoracoabdominal aortic aneurysms

Luca Bertoglio, MD,[a] Alessandro Grandi, MD,[a] Niccolò Carta, MD,[a] Tommaso Cambiaghi, MD,[b] Victor Bilman, MD,[c] Germano Melissano, MD,[a] *and* Roberto Chiesa, MD,[a] *Milan, Italy; Houston, Tex; and Rio de Janeiro, Brazil*

N = 268 patients with adequate CTA only atherosclerotic degenerative TAAAs were evaluated.

E-NSIDE: 43%

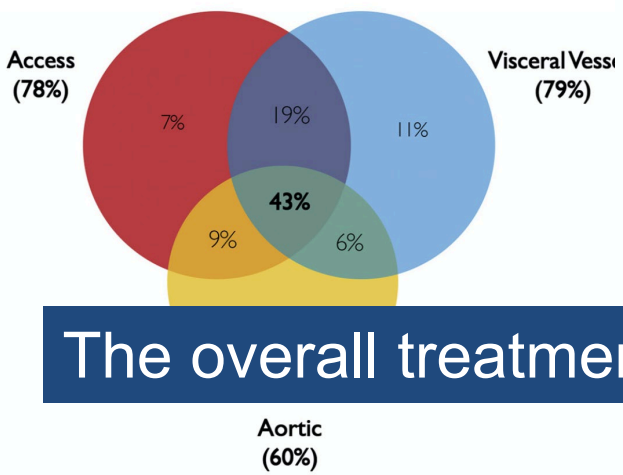

TAMBE: 33%

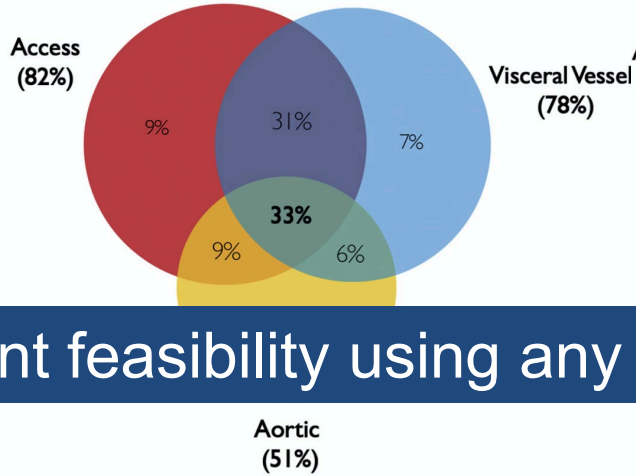

T-BRANCH: 39 %

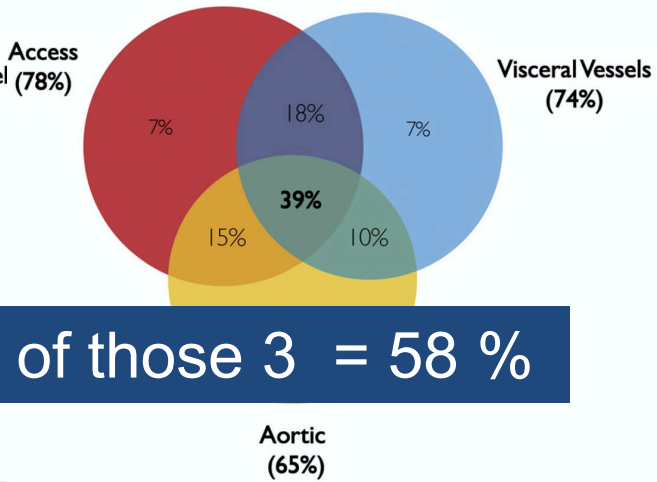

The overall treatment feasibility using any of those 3 = 58 %

EVMS Eastern Virginia Medical School | SENTARA®

Off the shelf Devices: Reality

OTS Treatment Options

PMEGs

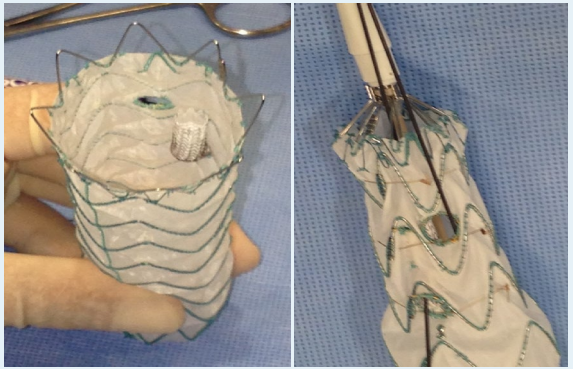

Labor intense
Delivery issues
Technically demanding
Component separation
Durability

ChEVAR

Technically easier
Stents compatibility
Gutter leaks
Chimney compression

ChEVAS

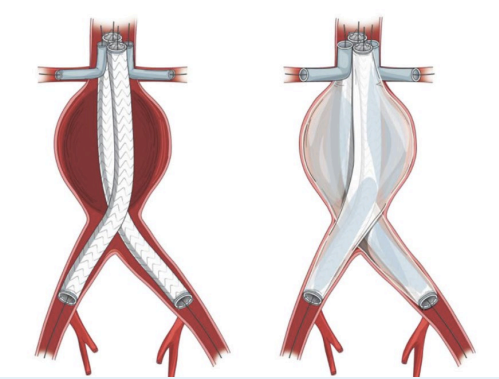

Not Approved
Not Available
Gutter leaks
Chimney compression

OTS Treatment Options: In Situ Laser Fenestrations

History

- 55 year-old female seen for follow up of type B aortic dissection (TBAD) with thoracoabdominal aneurysmal degeneration
  - 2005 – Open thoracic aortic repair for ruptured TBAD
  - 2014 – Open infrarenal aortic aneurysm repair with paravisceral septum fenestration
- Now with 6 cm TAAA



OTS Treatment Options: In Situ Laser Fenestrations for TAAA

ISLF SMA

SMA completion

RRA completion

Completion

OTS Treatment Options: In Situ Laser Fenestrations for TAAA

3D CTA 2 yrs post 4 vs ISLF

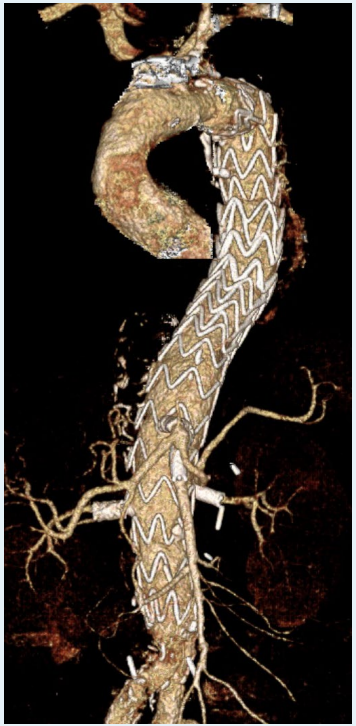

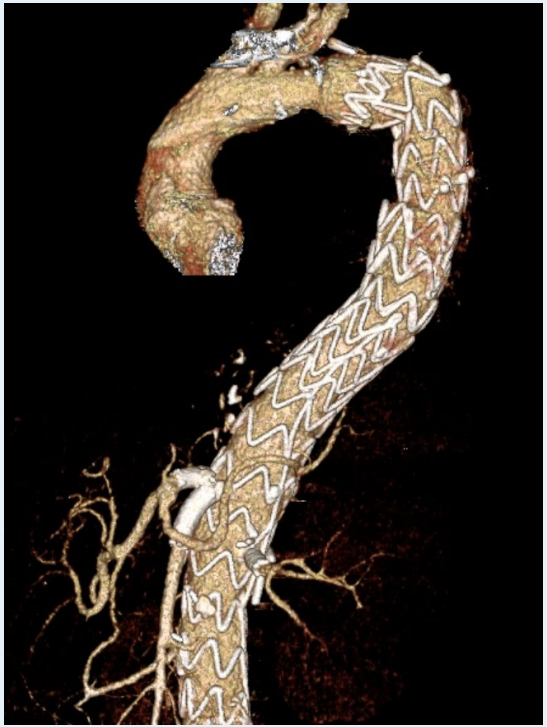

OTS Treatment Options: In Situ Laser Fenestrations

Visceral branch localization

Combination of Fusion imaging and Pre-stenting of visceral branches

RRA Laser Fenestration

LRA Laser Fenestration

Completion aortogram after 3 vessels in situ fenestrations

In Situ Visceral Fenestration: Combination of techniques

Large Type III TAAA with acute take off of the SMA and RRA

Pre-stenting of 3 vessels and celiac plug

Pre-wiring of all 3 vessels Before TEVAR deployment

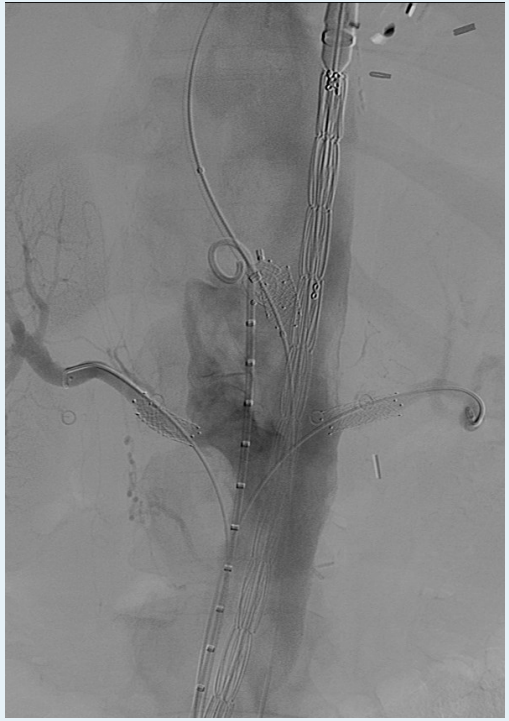

LRA after laser fenestration

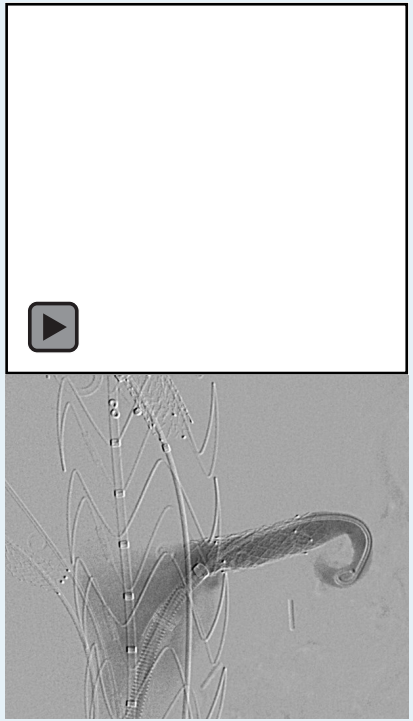

In Situ Visceral Fenestration: Combination of techniques

SMA Chimney

RRA laser fenestration
TourGuide for wiring

VBX advance
RRA stented

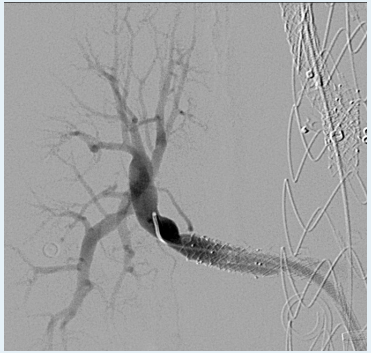

Completion angiogram

CTA @ 15 months

Chronic TBAD: RESET: How to fix a TAAA with an 8Fr Sheath

Zone 2 TEVAR with LSA Laser Fenestration
For rapidly expanding c TBAD

Uneventful recovery and discharged POD # 5

Returns to ED 2 years later
Abdominal & back pain
High Frailty

Chronic TBAD: RESET

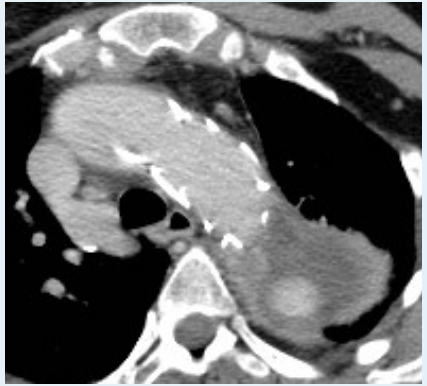

No proximal type I endoleak

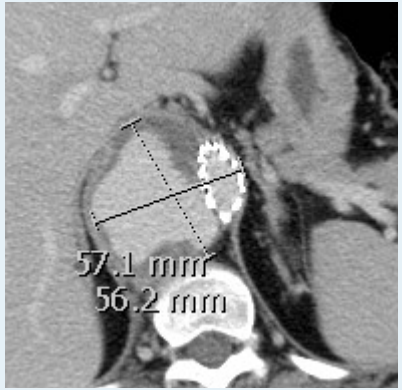

6 cm Distal thoracic aorta

Distal right iliac reentry

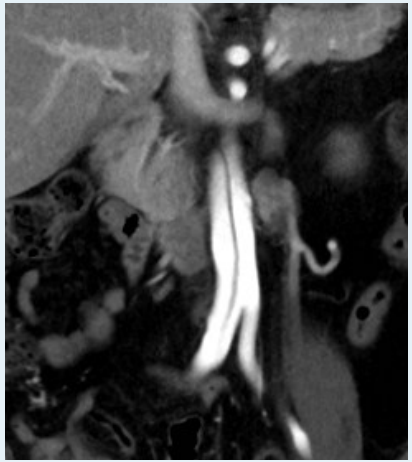

8 cm proximal thoracic aneurysm

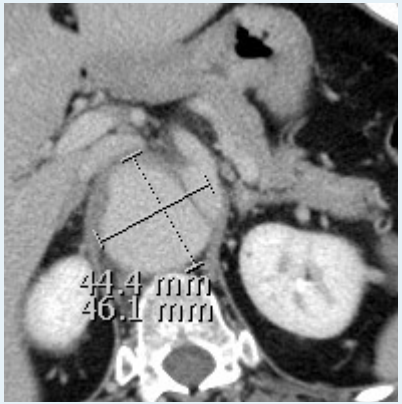

5cm paravisceral aorta

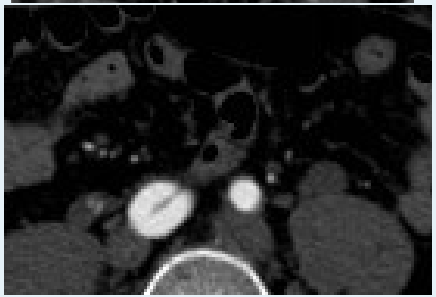

Chronic TBAD: RESET

Small retro SMA reentry

Options:

1. Open TAAA repair
2. Visceral debranching & aortoiliac graft with staged TEVAR
3. FEVAR
4. ChEVAR
5. RESET

Chronic TBAD: RESET

Paravisceral aortogram

Paravisceral aortogram with iliac reentry occlusion

RAO view of Paravisceral reentry angiogram

Catheterization of the false lumen

Chronic TBAD: RESET

Obliteration of the reentry after septal plug deployment

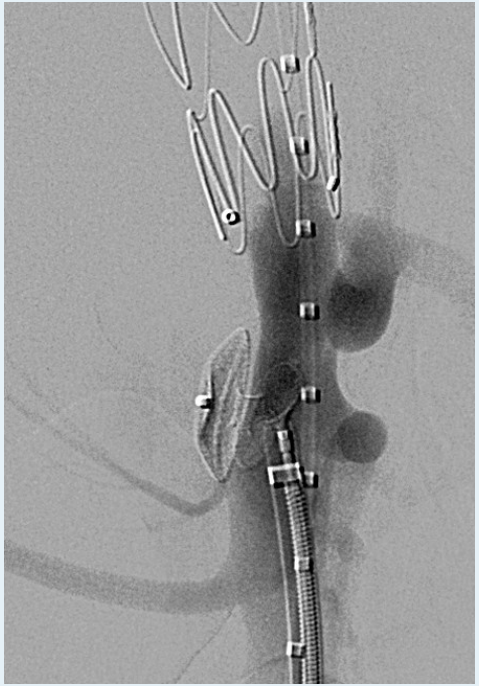

covered stent for iliac reentry

Completion angiogram

Chronic TBAD: RESET

Thrombosed false lumen

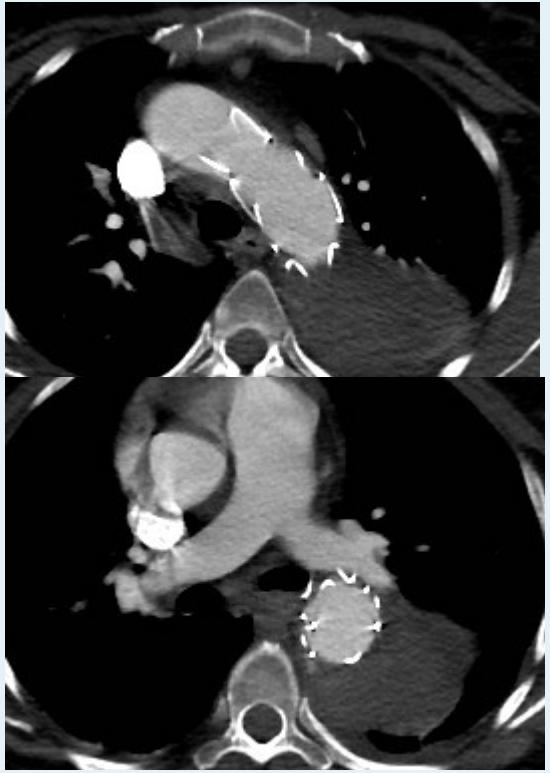

8 cm proximal thoracic aneurysm with patent false lumen

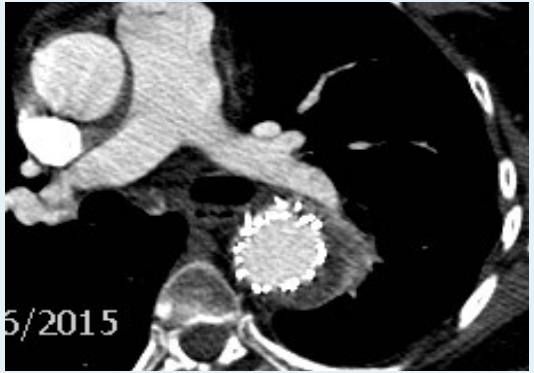

CTA @ 4 months

3 cm proximal thoracic aneurysm with thrombosed false lumen

CTA @ 7 year

Open Thoracoabdominal aortic surgery: Why choose this ?

Open Thoracoabdominal aortic surgery: Instead of choosing this ?

Endovascular repair in Hybrid Room

Minimally invasive
Percutanous Access
Lower mortality and morbidity

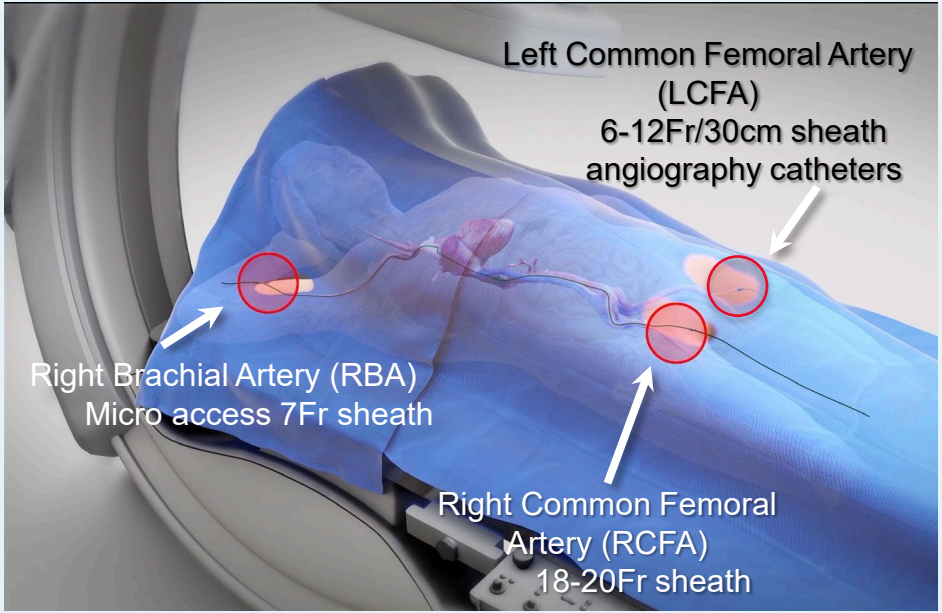

Thank you

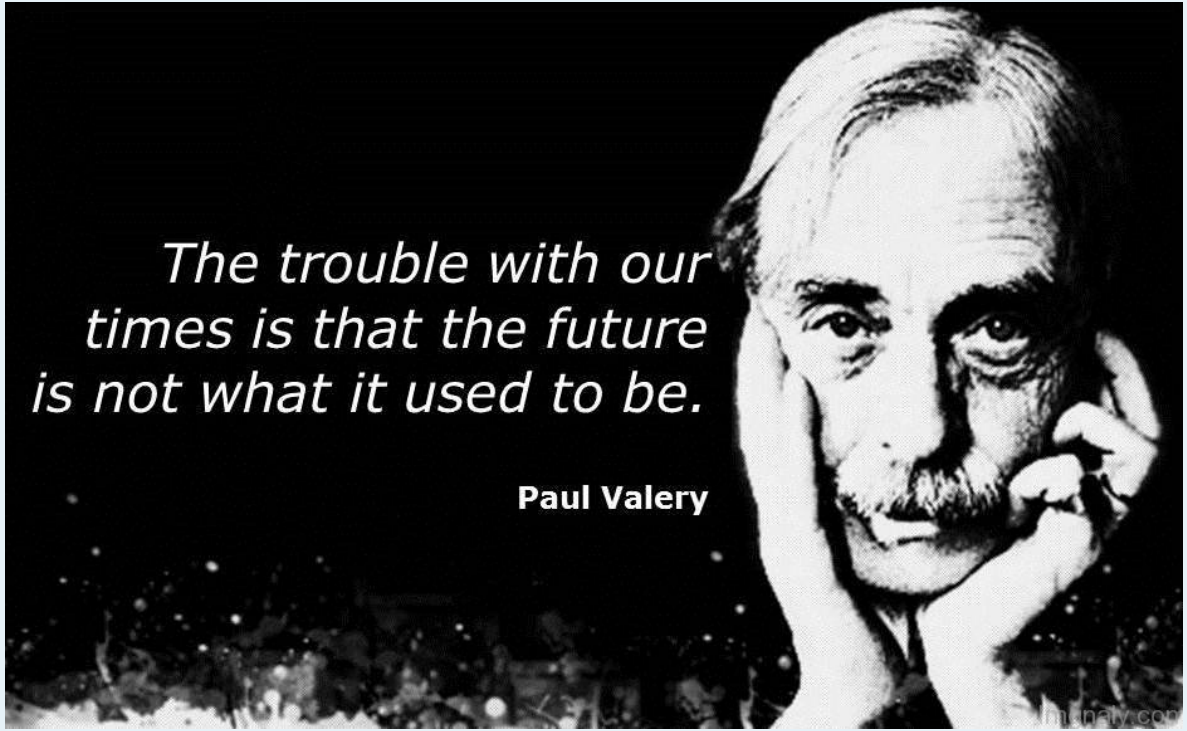
The trouble with our
times is that the future
is not what it used to be.
Paul Valery